



Pre-trabeculectomy intravitreal injections of bevacizumab for treating neovascular glaucoma in diabetic patients

Intravitrealna injekcija bevacizumaba pre trabekulektomije za lečenje neovaskularnog glaukoma kod bolesnika sa dijabetesom

Ivan Marjanović*, Marjan Marjanović†, Ranko Gvozdrenović*, Marija Marjanović‡, Vujica Marković*, Marija Božić*, Vesna Marić*, Antonio Martinez§

University of Belgrade, Faculty of Medicine, Clinical Center of Serbia, *University Eye Clinic, †Cardiology Clinic, Belgrade, Serbia; University Business Academy, ‡Faculty of Stomatology, Pančevo, Serbia; Science Research and Sports, §Clinical Research Department, Ames, La Coruna, Spain

Abstract

Background/Aim. Neovascular glaucoma (NVG) is a secondary glaucoma caused by occlusion of the trabecular network of newly formed blood vessels. The aim of this study was to evaluate the efficacy and safety of intravitreal injections of bevacizumab before trabeculectomy with mitomycin C (MMC) for the treatment of NVG. **Methods.** A prospective and open-label study was conducted from May 2013 to December 2014 on consecutive NVG patients who underwent intravitreal injections of bevacizumab and a primary trabeculectomy with MMC. All patients were followed-up at least for 12 months. Success was defined as an intraocular pressure (IOP) of ≤ 21 mm Hg with or without topical ocular hypotensive medication. **Results.** Fourteen eyes of 12 diabetic patients fulfilled the respective demands of the inclusion and exclusion criteria. The

mean (\pm standard deviation) follow-up period was 15.0 (± 2.0) months (range, 12 to 19 months). After one year of follow-up, 11 (78.6%) eyes had an IOP ≤ 21 mmHg. The mean IOP was significantly reduced from 42.4 (± 9.7) mmHg preoperatively to 18.4 (± 2.9) mmHg postoperatively ($p < 0.0001$). Regarding surgical complications, 6 months of trabeculectomy, hyphaema was observed in 3 (21.4%) eyes, macular edema in one (7.1%) eye and recurrence of neovascularization requiring intravitreal bevacizumab injection in 2 (14.2%) eyes. **Conclusion.** Preoperative intravitreal bevacizumab may be effective as adjunctive treatment for trabeculectomy with mitomycin-C for neovascular glaucoma patients.

Key words: diabetes mellitus; glaucoma, neovascular; bevacizumab; mitomycin; trabeculectomy; treatment outcome.

Apstrakt

Uvod/Cilj. Neovaskularni glaukom (NVG) je sekundarni glaukom uzrokovan okluzijom mreže novoformiranih krvnih sudova. Cilj rada bio je procena efikasnosti i sigurnosti intravitrealne injekcije bevacizumaba pre trabekulektomije sa mitomicinom C (MMC) u lečenju NVG. **Metode.** Prospektivna i *open-label* studija sprovedena je od maja 2013. do decembra 2014. na uzorku bolesnika sa NVG, kojima je data intravitrealna injekcija bevacizumaba i koji su bili podvrgnuti primarnoj trabekulektomiji sa MMC. Svi bolesnici su bili praćeni najmanje 12 meseci. Uspeh je bio definisan kao intraokularni pritisak (IOP) od ≤ 21 mm Hg, uz ili bez topikalne okularne hipotenzivne terapije. **Rezultati.** Četrnaest očiju od 12 bolesnika sa dijabetesom je ispunjavalo odgovarajuće kriterijume za uklanjanje u studiju. Prosečni (\pm standardna devijacija) period praćenja bio je 15,0 ($\pm 2,0$)

meseci (opseg, 12 do 19 meseci). Posle jedne godine praćenja kod 11 (78,6%) očiju IOP je bio ≤ 21 mmHg. Prosečna vrednost IOP je bila značajno smanjena sa 42,4 ($\pm 9,7$) mmHg preoperativno na 18,4 ($\pm 2,9$) mmHg postoperativno ($p < 0,0001$). Što se tiče hirurških komplikacija, šest meseci nakon trabekulektomije, hifema je bila uočena kod 3 (21,4%) oka, makularni edem na 1 (7,1%) oku, a recidiv neovaskularizacije sa potrebom davanja intravitrealne injekcije bevacizumaba kod 2 (14,2%) oka. **Zaključak.** Preoperativni intravitrealni bevacizumab može biti delotvoran kao pomoćna metoda lečenja trabekulektomijom sa mitomicinom-C kod bolesnika sa neovaskularnim glaukomom.

Ključne reči: dijabetes melitus; glaukom, neovaskularni; bevacizumab; mitomicini; trabekulektomija; lečenje, ishod.

Introduction

Neovascular glaucoma (NVG) is a secondary glaucoma caused by occlusion of the trabecular network of newly formed blood vessels. When new blood vessels appear within the anterior chamber angle, aqueous outflow can be compromised with extension of these new vessels across the scleral spur and subsequent obstruction of the trabecular meshwork. The new blood vessels are usually accompanied by a fibrous membrane, and contraction of this membrane results in formation of peripheral anterior synechiae and progressive angle closure. Neovascularization is caused by proliferative diabetic retinopathy (PDR), central retinal vein occlusion (CRVO), and ocular ischemic syndrome (OIS)¹.

Surgical procedures such as trabeculectomy with anti-metabolite agents, are often used to manage elevated intraocular pressure in NVG patients. Intraoperative mitomycin-C (MMC) during trabeculectomy (TMC) may be considered as the gold standard for glaucoma surgical treatment².

Anti-vascular endothelial growth factor (anti-VEGF) represents an alternative treatment for neovascular glaucoma^{3,4}.

Intravitreal bevacizumab (IVB) injection has been shown to reduce ocular neovascularization and vascular permeability in patients with ischemic retinal diseases and age-related macular degeneration, firstly reported in 2006^{5,6}. Additionally, IVB caused regression in the anterior chamber angle neovascularization, providing better intraocular pressure (IOP) control in NVG patients in open angle stage^{7,8}.

The aim of this study was to evaluate the efficacy and safety of intravitreal injections of IVB, administered preoperatively, as adjunctive therapy for trabeculectomy with MMC in neovascular glaucoma patients.

Methods

A prospective and open-label study was conducted from May 2013 to December 2014 on consecutive patients with NVG who underwent a TMC with preoperative intravitreal application of bevacizumab.

Recruitment was ongoing for a period of 6 months with an aim to collect a sufficient number of patients.

The off-label use of bevacizumab (Avastin; Roche Pharmaceuticals, Basel, Switzerland) was also approved by the Institutional Review Board (IRB) of the University Eye Clinic, Clinical Centre of Serbia, Belgrade. Written informed consent about the glaucoma treatment was obtained from all patients after thorough discussion of the potential benefits and risks of IVB injection.

Neovascular glaucoma was defined as the presence of iris and/or anterior chamber angle neovascularization with extensive fibrous synechiae (at least 2/3 of the angle area) in the angle and an IOP equal or higher than 21 mmHg with antiglaucoma medication, either topical or systemic. Eyes with no light perception were excluded from the study.

Procedures

Neovascular glaucoma patients who were included in the study, before arriving at our glaucoma department on the

surgical treatment, had several retinal photocoagulation (standard spot size 200 μ m, 300-400 spots per treatment, average 3 sessions and average 2100 spots) sessions covering average 2/3 of retina, but not complete panretinal photocoagulation before neovascular glaucoma forming.

Intravitreal injection of 50 mL (1.25 mg; ec. 0.5 mg/0.05 mL) of bevacizumab through 30 G needle were inserted through the pars plana, under topical anesthesia with 4% lidocaine. Monitoring of regression of iris neovascularization lasted for two weeks. A fornix-based conjunctival flap technique for trabeculectomy with 0.2 mg/mL MMC was performed within 2 weeks – 1 month after IVB.

Trabeculectomy was performed by the same experience surgeon (IM). The trabeculectomy procedure included creation of a fornix-based conjunctival flap and a 3 x 4 mm, half-thickness scleral flap. Small pieces of surgical sponge soaked in 0.2 mg/mL MMC were then inserted under the conjunctival flap for up to 2 minutes. Trabeculectomy was done with a Kelly Descemet's Membrane Punch (Inami, Tokyo, Japan). After that, a peripheral iridectomy was done. The scleral flaps were closed with 10-0 nylon sutures, and the conjunctival flap was closed with an 8.0 absorbable suture.

The visual acuity, IOP, anti-glaucoma medications, and the appearance of the iris neovascularization (NVI) by ophthalmoscopy were estimated at baseline and post-IVB and before euclectomy (pre-trab) and after trabeculectomy (post-trab). The intraoperative and postoperative complications were also recorded.

Postoperatively, patients were examined at the day 1, the day 7, every month till month 3, and every 3 months thereafter.

IOP was measured by Goldmann applanation tonometry. The mean of two IOP measurements immediately before trabeculectomy were adopted as the preoperative IOP.

Surgical success was defined as IOP of ≤ 21 mm Hg with or without topical ocular hypotensive medication. On the other hand, surgical failure was defined as insufficient IOP reduction (IOP ≥ 22 mmHg, $< 20\%$ IOP reduction, use of a systemic carbonic anhydrase inhibitor, or further glaucoma surgeries), devastating complications (loss of light perception, *phthisis bulbi*, and *endophthalmitis*), or significant hypotony (IOP equal or lower than 5 mmHg continuing six months and until the last follow-up visit or hypotony that required intervention).

Statistical analysis

Statistical analysis was performed using SPSS software (IBM SPSS Statistics 20, IBM Corp., New York) and Stata software (version 13.1; StataCorp, TX). Descriptive statistics [mean \pm standard deviation (SD)] and 95% confidence intervals (95% CIs) were used for demographic and clinical characteristics.

Data were tested for normal distribution using the Kolmogorov-Smirnov test. For comparisons between baseline and post-IVB, and for pre-trab and post-trab, mixed-effects models using clustered robust standard errors by Stata software were used to account for the correlation of both eyes in

the same patient. For all analyses, a p -value of < 0.05 was considered statistically significant.

Results

Fourteen eyes of 12 diabetic patients were included in the study. Their main clinical and demographic characteristics are shown in Table 1.

Table 1
Baseline demographic and clinical characteristics of diabetic patients with neovascular glaucoma (14 eyes of 12 patients)

Characteristics	Values
Age (years)	
mean (\pm SD)	57.3 (12.0)
range	28–69
Sex, n (%)	
male	9 (75.0)
female	3 (25.0)
Pre-trabeculectomy IOP, mm Hg	
mean (\pm SD)	42.4 (9.7)
range	30–69
Pre-trabeculectomy VA	
mean (\pm SD)	0.35 (0.30)
range	0.01–0.5
Antiglaucoma medications, n (%)	
beta-blockers	14 (100)
prostaglandin analogues	14 (100)
CAI	14 (100)
Systemic medications, N (%)	
HBP	12 (100)
diabetes	12 (100)

SD – standard deviation; n – number of eyes;

N – number of patients; IOP – intraocular pressure; VA – visual acuity; CAI – carbonic anhydrase inhibitors; HBP – high blood pressure

Two weeks post-injection, all cases showed complete regression of the iris an angle new vessels. Recurrence of iris neovascularization was observed in 2 (14.2%) eyes at month 6 where reinjection was done; a second recurrence of neovascularization was not observed.

The mean (\pm SD) preoperative IOP was 42.4 (\pm 9.7) mmHg. TMC significantly reduced IOP at all time point measurements ($p < 0.0001$) (Figure 1).

After one year of follow-up, 11 (78.6%) eyes had IOP \leq 21 mmHg and were considered as success.

The mean (\pm SD) number of antiglaucoma medications at baseline was significantly higher, 3.0 (\pm 0.0) than that reported at the month 12 after the treatment, 1.1 (\pm 1.5) ($p = 0.0003$).

Visual acuity did not show any significant change between pre-trab measurements [0.35 (\pm 0.3)] and after one year of follow-up [0.40 (\pm 0.3)] ($p = 0.150$).

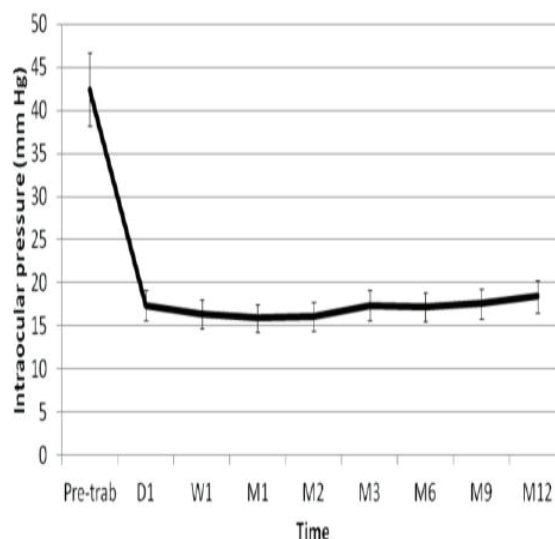


Fig. 1 – Evolution of intraocular pressure (IOP) over the length of follow-up. The mean IOP, at all point measured, was significantly lower than the pre-trabeculectomy IOP ($p < 0.0001$).

Pre-trab – Pre-trabeculectomy; D – day; W – week; M – month.

As regards complications, hyphaema was seen in 3 (21.43%) eyes at the early postoperative period; at month 6, 1 (7.1%) patient had macular edema and 2 (14.2%) eyes showed recurrence of neovascularization requiring IVB injection.

Discussion

The results of our study suggested that intravitreal injections of bevacizumab, administered preoperatively, as adjunctive therapy for trabeculectomy with MMC in neovascular glaucoma patients is effective not only for reducing IOP but also for preventing bleeding.

Additionally, our study also found a complete regression of the iris neovascularization in all the eyes 2 weeks after IVB injection. These results are in agreement with Iliev et al.³ and Marey and Ellakwa⁹ who reported complete regression of neovascularization at the end of follow-up period in 100% of cases. Conversely, Oshima et al.⁷ observed complete regression in only 29% of their cases.

The rate of reinjection was lower than that reported by Oshima et al.⁷ (29% at the month 2 after the treatment) and Marey and Ellakwa⁹ (20% at the month 4 and 70% at the month 8 after the treatment).

The success rate of trabeculectomy with MMC in NVG is quite low¹⁰. In our study, 11 (78.6%) eyes had IOP \leq 21 mmHg after 12 months of follow-up. These results are in line with those reported by Marey and Ellakwa⁹ who reported a success rate of 77.8%. However, it is slightly lower than that observed by Elmekawey and Khafagy¹¹, who found a success rate (IOP between 10 and 21 mm Hg with or without medication) of 90%, but using ranibizumab as adjunctive therapy for the TMC.

Regarding visual acuity, our study did not find any significant improvement after the treatment. This is in contradiction with Marey and Ellakwa⁹ who observed a significant improvement of the visual acuity ($p = 0.0001$).

This study has some limitations that should be mentioned: an open-label design, a single centre study, a limited number of patients. Nevertheless, the fact that statistical analyses were conducted in a masked fashion could reduce the potential for bias.

Conclusion

Intravitreal bevacizumab, administered preoperatively as adjunctive therapy for trabeculectomy with mitomycin-C in neovascular glaucoma patients, successfully produced regression of iris neovascularization and also increased the success rate of the trabeculectomy with mitomycin-C. Further studies are needed to elucidate the long term effect of trabeculectomy with adjunctive bevacizumab injections in neovascular glaucoma patients.

R E F E R E N C E S

1. Sivak-Callcott JA, O'Day DM, Gass JD, Tsai JC. Evidence-based recommendations for the diagnosis and treatment of neovascular glaucoma. *Ophthalmology* 2001; 108(10): 1767–76; quiz 1777, 1800.
2. Rulli E, Biagioli E, Riva I, Gambirasio G, De Simone I, Floriani I, et al. Efficacy and safety of trabeculectomy vs nonpenetrating surgical procedures: a systematic review and meta-analysis. *JAMA Ophthalmol* 2013; 131(12): 1573–82.
3. Iliev ME, Domig D, Wolf-Schnurrbusch U, Wolf S, Sarra GM. Intravitreal bevacizumab (Avastin) in the treatment of neovascular glaucoma. *Am J Ophthalmol* 2006; 142(6): 1054–6.
4. Yoshida N, Hisatomi T, Ikeda Y, Kobno R, Murakami Y, Imaki H, et al. Intravitreal bevacizumab treatment for neovascular glaucoma: histopathological analysis of trabeculectomy specimens. *Graefes Arch Clin Exp Ophthalmol* 2011; 249(10): 1547–52.
5. Spaide RF, Fisher YL. Intravitreal bevacizumab (Avastin) treatment of proliferative diabetic retinopathy complicated by vitreous hemorrhage. *Retina* 2006; 26(3): 275–8.
6. Iturralde D, Spaide RF, Meyerle CB, Klančnik JM, Yannuzzi LA, Fisher YL, et al. Intravitreal bevacizumab (Avastin) treatment of macular edema in central retinal vein occlusion: a short-term study. *Retina* 2006; 26(3): 279–84.
7. Oshima Y, Sakaguchi H, Gomi F, Tano Y. Regression of iris neovascularization after intravitreal injection of bevacizumab in patients with proliferative diabetic retinopathy. *Am J Ophthalmol* 2006; 142(1): 155–8.
8. Wakabayashi T, Oshima Y, Sakaguchi H, Ikuno Y, Miki A, Gomi F, et al. Intravitreal bevacizumab to treat iris neovascularization and neovascular glaucoma secondary to ischemic retinal diseases in 41 consecutive cases. *Ophthalmology* 2008; 115(9): 1571–80, 1580.e1–3.
9. Marey HM, Ellakwa AF. Intravitreal bevacizumab with or without mitomycin C trabeculectomy in the treatment of neovascular glaucoma. *Clin Ophthalmol* 2011; 5: 841–5.
10. Kinuchi Y, Sugimoto R, Nakae K, Saito Y, Ito S. Trabeculectomy with mitomycin C for treatment of neovascular glaucoma in diabetic patients. *Ophthalmologica* 2006; 220(6): 383–8.
11. Elmekavey H, Khafagy A. Intracameral ranibizumab and subsequent mitomycin C augmented trabeculectomy in neovascular glaucoma. *J Glaucoma* 2014; 23(7): 437–40.

Received on May 31, 2017.

Revised on July 29, 2018.

Accepted on July 31, 2018.

Online First September, 2018.